

## Extracorporeal Shock Wave Therapy versus Surgical Treatment in Calcifying Tendinitis and Non Calcifying Tendinitis of the Supraspinatus Muscle

M. Haake<sup>1</sup>, M. Rautmann<sup>2</sup> and T. Wirth<sup>1</sup>

<sup>1</sup>Orthopaedic Department of the Philipps-University, Marburg, Germany

<sup>2</sup>Orthopaedic Department of Klinikum Mannheim, Faculty of Medicine, University of Heidelberg, e-mail: haake2@mail.uni-marburg.de

**Summary:** The authors performed a study to compare the short-term clinical outcome between three methods for failed conservative treatment of the supraspinatus muscle tendinitis, extracorporeal shock wave therapy (ESWT) and open or arthroscopical subacromial decompression.

60 patients treated by ESWT or treated surgically (14 open, 16 arthroscopically) were included and assessed preoperatively and 3 months postoperatively with the subjective shoulder rating system (SSRS score). Another parameter investigated was a cost analysis with emphasis on the time of unfitness for work.

There was a considerable score increase in all three groups three months after intervention with a change of 24 and 25 points in the surgical subgroups and of 14 points in the ESWT group. This led to 40% good/very good results in the open surgical group, 62% good/very good results in the arthroscopically treated group and 67% good/very good results in the ESWT group. The time of unfitness for work and costs for treatment were lowest in the ESWT group.

ESWT appears to be an effective and relatively inexpensive treatment for supraspinatus muscle tendinitis and should be considered before surgical treatment is employed.

**Key words:** Extracorporeal shock wave therapy – ESWT – Open and arthroscopic subacromial decompression – Cost of illness

Extracorporeal shock wave therapy (ESWT) represents a new method of treating insertion tendopathies for cases unsuccessfully treated by conservative means; its value has not yet been definitely assessed. The literature differentiates between high and low energy applications, in which the division into different energy areas has been determined in a non-standardised way. Dahmen et al. [2] reported first, then Haist et al. [5], Loew et al. [8] and Rompe et al. [13] on ESWT treatment of insertion tendopathies and calcifying tendinitis with a success rate of 65% to 75%. As yet there have been no meaningful prospective placebo-controlled studies for treating insertion tendopathies of the shoulder. In the year 1996, the number of applications in the orthopaedic area, with an estimated 60.000 – 100.000 patients, has finally exceeded the number of applications of lithotripsy in urology.

Unsuccessful conservative treatment also was the prerequisite for indicating

surgical treatment (OP) for tendinitis of the supraspinatus muscle by enlarging the supraspinatus passage through anterior acromioplasty according to Ellman or Neer [4, 9]. In cases with calcifying tendinitis the calcified area is optionally removed in addition. Basically both arthroscopic and open anterior acromioplasty are possible. Results for arthroscopic acromioplasty (in the literature: from 69% to 95% good results) are equivalent to those for the open technique [1, 10].

The aim of the study was to compare the clinical outcome of three different methods indicated for failed conservative treatment for supraspinatus tendinitis. Secondly, a cost analysis was performed with special view of the postoperative unfitness for work.

### Material and methods

The patient population was made up of a total of 60 patients with a clinical picture of a chronic tendinitis of the supraspinatus muscle with or without calcifying tendinitis. The key objective criterion for clinical success was the Subjective Shoulder Rating System (SSRS) 12 weeks after the operation [7, 16]. Data collection was carried out prospectively in a non-randomised patient population.

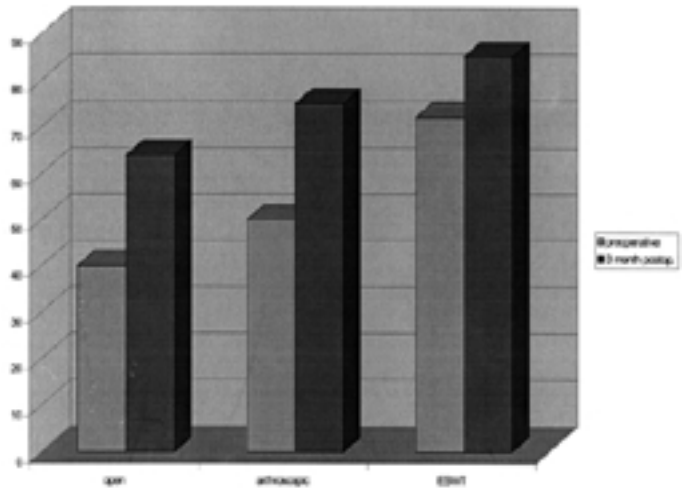
The indication for ESWT or OP was given analogously when patients had

Code Méary: 

Correspondence to: M.Haake



**Fig. 1**  
ESWT application to the right shoulder



**Fig. 2**  
Change of SRSS-Score before and after the intervention

been conventionally treated without success at least 6 months before ESWT / OP. The treatment was only carried out in the case of isolated chronic tendinitis of the supraspinatus muscle or chronic tendinitis of the supraspinatus muscle with type 1 or 2 calcific deposits according to Gärtner [5] with a minimum diameter of 1 cm.

In the period from March to December 1997 30 patients with an average age of 49.7 years (min. 32, max. 64) underwent ESWT. On the other hand, 30 patients with an average age of 51.1 years (min. 40, max. 60) with the same diagnosis were surgically treated with an acromioplasty (14 open/16 arthroscopically) according to Ellman [4] or Neer [9] between 1995 and 1997. If the patient presented with a calcifying tendinitis an open acromioplasty with lime deposit dissection was carried out.

A modified Storz Minilith SL1 lithotripter (Storz Medical, Switzerland) was used for the ESWT. In the case of calcifying tendinitis the locating was carried out by axial view X-ray. Two treatments each of 2000 impulses of the energy flow density  $E_+ = 0.35 \text{ mJ/mm}^2$  were administered a week apart. In the case of supraspinatus tendinitis the locating was implemented by inline ultrasound on the base of the tendon (Fig. 1). Depending on the pain tolerance the energy flow density used was  $E_+ = 0.08\text{-}0.14$

$\text{mJ/mm}^2$  without local anaesthetic, for 3 treatments a week apart, each of 2000 impulses.

Each set of clinical results was evaluated using the SSRS according to Wülker [7, 16] directly before and 12 weeks after the ESWT. A score greater than/equal to 80 points was rated a success. Also a score greater than/equal to 70 points was rated a success, when the score increased by 30 points after treatment. For the rest of the patients a score increase of at least 15 points was assessed as satisfactory, the remainder graded as poor.

Cost analysis included the actual costs of the hospital stay, the ESWT application, the postoperative or post-ESWT rehabilitation costs and the indirect costs caused by the patient's inability to work.

## Results

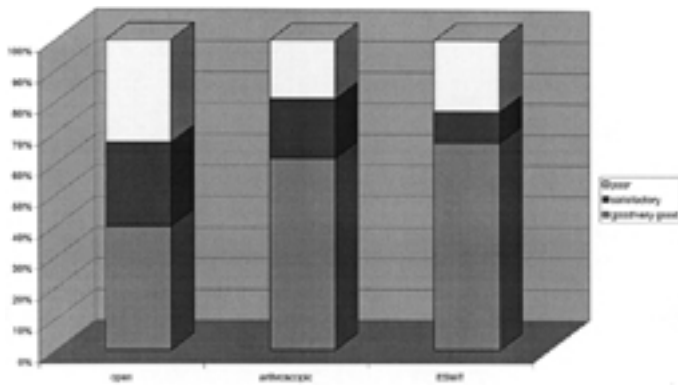
The surgical subgroup (14 treated by open, 16 by arthroscopic acromioplasty) consisted of 24 patients with chronic supraspinatus muscle tendinitis and 6 patients with a calcifying tendinitis. 27 of these 30 patients were fully employed. The average preoperative SSRS-Score was 45 points (19-74 points). The ESWT subgroup contained 8 patients with a pure chronic tendinitis of the supraspinatus muscle and 22 with a calcifying

tendinitis. All patients were fully employed. The preoperative SRSS-score averaged 72 points (57-86).

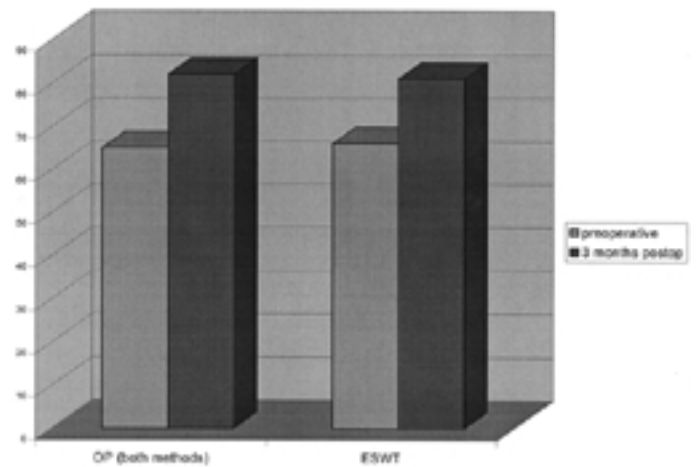
The postoperative change of the SSRS-score is given in figure 2. Patients who were operated on by an open procedure had a lower preoperative score than the other groups. The postoperative score was also lowest in the open surgery group. The score increase, however, was found to be almost equal in both surgical subgroups.

After evaluating the score, of the patients who had been operated on (open and arthroscopically) 57% (= 17 patients) had a good or very good, 20% (= 6 patients) a satisfactory and 23% (= 7 patients) a poor result. The evaluation of the ESWT patients resulted in 67% (= 20 patients) good or very good, 10% (= 3 patients) satisfactory and 23% (= 7 patients) poor results. Fig. 3 illustrates the success rate of the three subgroups. The radiological disintegration rate of the lime depot was 45% 12 weeks after ESWT, and 83% after the operation.

Due to the different values in the average SSRS pre-treatment score each minimum and maximum pre treatment score was ascertained for both populations. The score in the ESWT group lay between 57 and 86 points, in the surgical group between 19 and 74. By forming the points overlap from both populations



**Fig. 3**  
Distribution of clinical results in all subgroups



**Fig. 4**  
Pre- and postoperative SSRS-Score of the statistically adjusted subgroups

those patients who showed a minimum pre-score of 57 points and a maximum pre-score of 74 points could be identified. It transpired that in the shock wave group 20 patients and in the surgical group 6 patients fulfilled the aforementioned terms of reference. A random generator (statistics program SPSS) was used to select six out of the 20 ESWT patients with an appropriate pre-score. In this way a comparison could be made between the two resultant subgroups.

After this streamlining there was a success rate of 67% good and very good results (an increase from 65 to 82 points) in the surgical subgroup, with an unaltered success rate in the ESWT subgroup. Fig. 4 illustrates the SSRS-Score of these statistically selected comparable subgroups.

The average overall cost per patient in the surgical subgroup was EUR 13.260 or EUR 23.400 (depending on how unfitness for work was calculated [3, 11]). Of this EUR 3.150 was related to the hospital stay including the operation, EUR 390 to outpatient physiotherapy, and EUR 9.710 or EUR 19.440 to the period when the patient was unfit for work. In the cost analysis average overall costs in the ESWT subgroup were calculated at EUR 2.670 or EUR 4.420 per patient. Of this EUR 658 was apportionable to the shock wave therapy itself, EUR 263 to outpatient physiotherapy and EUR 1.750 or EUR 3.500 to the costs of being unfit for work. The portion of the costs caused by

the patient being unfit for work was 2/3 of the overall costs.

### Discussion

Arthroscopic and open acromioplasty have become standard procedures for surgically treating the supraspinatus muscle tendinitis. Both operations have been reported to be equal with regards to the clinical outcome with a generally shorter rehabilitation time following the arthroscopic procedure [4, 12, 14, 15]. The arthroscopic procedures are known to allow earlier rehabilitation with a considerable shorter time off work [1]. Frequently it can be performed as an outpatient procedure [4].

The ESWT application has been performed on an outpatient basis as well, and a mean off work time of 7.7 days was recorded. All but three patients treated arthroscopically could return to work within 6 weeks after the operation. The average time of unfitness for work in the group treated by open surgery averaged 11 weeks. These data show that ESWT treatment can be an efficient method with short rehabilitation time. Further, a short follow up time is justified when unfitness for work is a key outcome parameter like in this study.

The clinical results of our surgical subgroups appeared to be rated worse than other results presented in the literature. The main reason for that is the

follow-up time of 3 months. It is known that the clinical outcome improves further with time. Nutton [10] showed, that there was an improvement of the UCLA-Score from a 28% success rate at 3 months to 85% success rate after 1 year following arthroscopic subacromial decompression. With this background, the results presented in this study are well in accordance with the published results for both open and arthroscopic subacromial decompression.

The clinical results twelve weeks after ESWT, measured on the SRSS score, showed a good and very good result in two thirds of cases. In comparison the radiological disintegration rate was only 45% versus 83% in the surgical groups. Both results were well within the range of the data published so far on the 12 weeks success rates of ESWT [8, 13]. Also for ESWT a further slight increase in the clinical score evaluation can be expected after one year [13].

The clinical results in the ESWT-group seem to be more favourable than in the surgical groups. However, the homogeneity of the groups varies with a tendency to lower preoperative scores in both surgically treated subgroups. By statistical adjustment comparable patients could be identified and separately analysed. These patients exhibited almost identical scores after surgical or ESWT-procedure. We conclude that both the ESWT and the surgical procedures have similar potential to success-

fully treat the chronic tendinitis of the supraspinatus muscle.

A directly randomised comparison would be desirable from a methodical point of view. Although both populations were tested prospectively for themselves, the direct comparison can only take place retrospectively for the reason that patients are not prepared to be also randomly picked in the operation group for a study with the choice of a shoulder operation versus ESWT.

The cost calculation also supports the concept of applying ESWT to patients with chronic supraspinatus tendinitis before surgery may be considered. Since the time the patient is unfit for work is the most costly economic factor, the ESWT treatment may have the first treatment priority in such cases. This study showed that any surgical intervention is more expensive due to the longer rehabilitation phase.

We conclude that there is a place for ESWT in the treatment of supraspinatus muscle tendinitis with or without calcification particularly for patients with a sufficient range of motion in the shoulder. For cases with reduced joint motion

due to capsular adhesions we recommend a primary surgical approach

## References

1. Checroun AJ, Dennis MG, Zuckerman JD (1998) Open versus arthroscopic decompression for subacromial impingement. A comprehensive review of the literature from at least 25 years. *Bull Hosp Jt Dis* 57: 145-151
2. Dahmen G, Meiss L, Nam V, Franke R, Goncharov V (1992) Extrakorporale Stoßwellentherapie (ESWT) im knochenahnen Weichteilbereich an der Schulter - Erste Therapieergebnisse *Extracta Orthop* 15: 25-29
3. De Girolamo, G (1991) Epidemiology and Social Costs of Low Back Pain and Fibromyalgia *Clin J Pain*; Vol 7, Suppl 1: 1-27
4. Ellman H, Kay SP (1991) Arthroscopic Subacromial Decompression for Chronic Impingement. *J. Bone Joint Surg* 73-B: 395-398
5. Gaertner J (1993) Tendinosis calcarea - Behandlungsergebnisse mit Needling. *Z Orthop* 131: 61-469
6. Haist J, Steeger D, Witzsch U, Bürger R, Haist U (1992) The extracorporeal shockwave therapy in the treatment of disturbed bone union. 7<sup>th</sup> Int Conference on Biomedical Engineering, Singapore, 222-224
7. Kohn D, Geyer M (1997) The subjective shoulder rating system. *Arch Orthop Trauma Surg* 116: 324-328
8. Loew M, Daecke W, Kusnierczak D, Rahmanzadeh M, Ewerbeck V (1999) Shock-wave therapy

is effective for chronic calcifying tendinitis of the shoulder. *J Bone Joint Surg* 81-Br: 863-867

9. Neer C (1972) Anterior acromioplasty for the chronic impingement syndrome in the shoulder. *J Bone Joint Surg* 54-A: 41-50
10. Nutton RW, McBirnie JM, Phillips C (1997) Treatment of chronic rotator cuff impingement by arthroscopic subacromial decompression. *J Bone Joint Surg* 79-B: 73-76
11. Pfföringer W (1997) Rückenschmerz-„Cost-of-illness“-Studie. *Z Orthop* 135; Suppl: Abstract 91
12. Rockwood, CA, Lyons, FR (1993) Shoulder Impingement Syndrome: Diagnosis, Radiographic Evaluation and Treatment with a Modified Neer Acromioplasty. *J Bone Joint Surg* 75-A: 409-423
13. Rompe J-D, Rumler F, Hopf C, Nafe B, Heine J (1995) Extracorporeal shock wave therapy for the calcifying tendinitis of the shoulder. *Clin Orthop* 321: 196-201
14. Roye RP, Grana WA, Yates CK (1995) Arthroscopic subacromial decompression: two - to seven year follow-up. *Arthroscopy* 11: 301-306
15. Sachs RA, Stone ML, Devine S (1994) Open vs. arthroscopic acromioplasty: A prospective randomized study. *Arthroscopy* 10: 248-254
16. Wülker, N, Kohn, D, Grimm, C (1991) Bewertung der Schulterfunktion mit unterschiedlichen Scores. *Orthop Praxis* 12: 750-754

Received September 18, 2000 / Accepted in final form December 02, 2000

## Comparaison entre la lithotripsie extracorporelle par ondes de choc (ESWT) et le traitement chirurgical de la tendinite calcifiante et non calcifiante du muscle du sus-épineux

**Résumé :** Les auteurs ont mené une étude sur le résultat clinique à court terme du traitement de la tendinite du muscle sus-épineux après échec du traitement conservateur à l'aide de trois techniques : la lithotripsie extracorporelle par ondes de choc (ESWT), la décompression sous-acromiale à ciel ouvert ou par arthroscopie.

Le groupe étudié comportait 30 patients traités par ESWT et 30 patients traités par chirurgie dont 14 à ciel ouvert et 16 par arthroscopie. La tendinite a été évaluée avant et 3 mois après l'intervention à l'aide du score SSRS, un système de cotation subjective pour l'épaule (score SSRS : subjective shoulder rating system). Un autre paramètre examiné était l'analyse des coûts mettant l'accent sur la durée d'incapacité de travail

Une amélioration considérable du score SSRS a été constatée trois mois après l'intervention dans les trois groupes, avec une évolution de 24 et 25 points dans les sous-groupes chirurgicaux et de 14 points dans le groupe ESWT. On a conclu à 40 % de bons/très bons résultats dans le groupe traité par chirurgie à ciel ouvert, 62 % de bons/très bons résultats dans le groupe traité par arthroscopie et 67 % de bons/très bons résultats dans le groupe ESWT. La durée de l'incapacité de travail et les coûts de traitement étaient les plus faibles dans le groupe ESWT. La lithotripsie extracorporelle par ondes de choc semble être un traitement efficace et relativement bon marché de la tendinite du muscle sus-épineux et devrait être envisagée avant de recourir au traitement chirurgical.

**Mots clés :** Lithotripsie extracorporelle par ondes de choc - ESWT - Décompression sous-acromiale - Coût de la maladie